

Harvard-MIT Division of Health Sciences and Technology

HST.121: Gastroenterology, Fall 2005

Instructors: Dr. Martin Carey, Dr. Raymond Chung, and Dr. Jonathan Glickman

# Vascular and Inflammatory Diseases of the Intestines

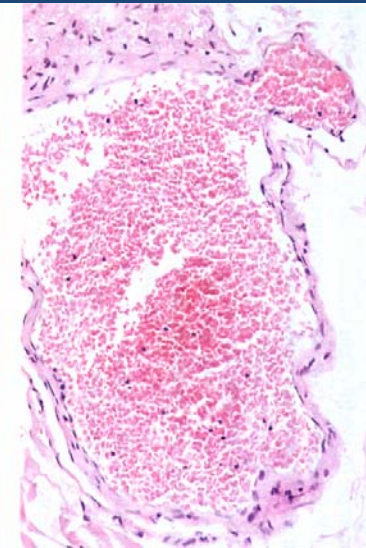
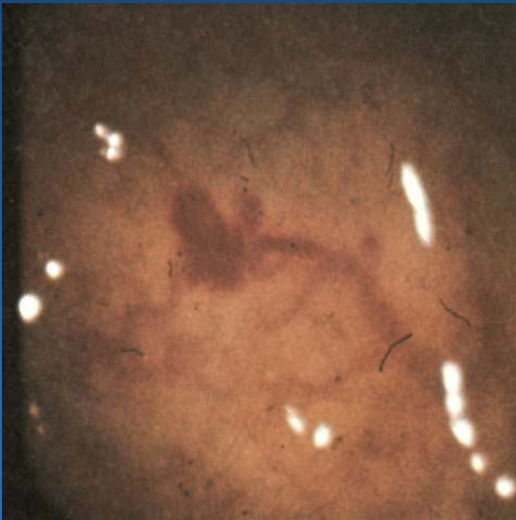
# Overview

- **Vascular disorders**
  - **Vascular “malformations”**
  - **Vasculitis**
  - **Ischemic disease**
- **Inflammatory disorders of specific etiology**
  - **Infectious enterocolitis**
  - **“Immune-mediated” enteropathy**
  - **Diverticular disease**
- **Idiopathic inflammatory bowel disease**
  - **Crohn’s disease**
  - **Ulcerative colitis**

# Sporadic Vascular Ectasia (Telangiectasia)

- Clusters of tortuous thin-walled *small* vessels lacking muscle or adventitia located in the mucosa and the submucosa
- The most common type occurs in cecum or ascending colon of individuals over the age of 50 and is commonly known as “**angiodysplasia**”
- Angiodysplasias account for 40% of all colonic vascular lesions and are the most common cause of lower GI bleeding in individuals over the age of 60

# Angiodysplasia

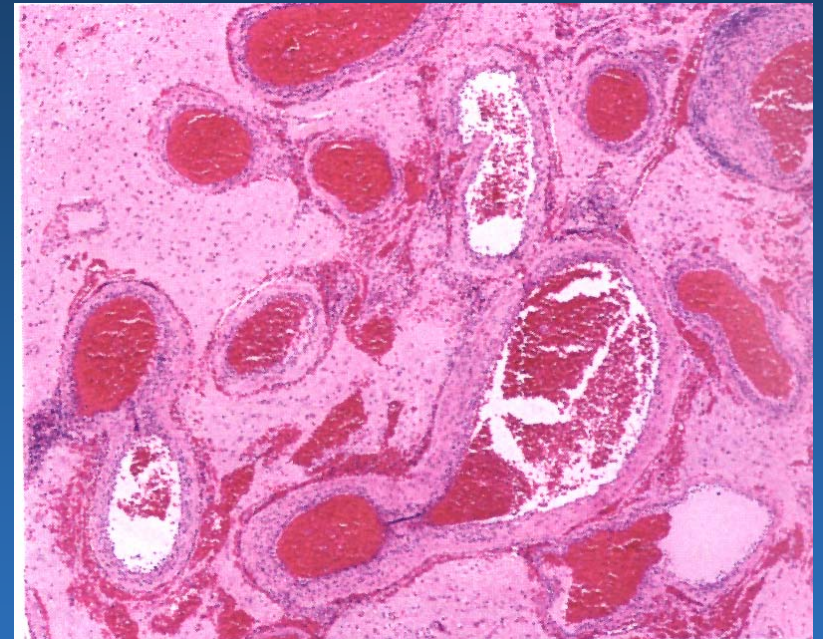


# Hereditary Vascular Ectasia

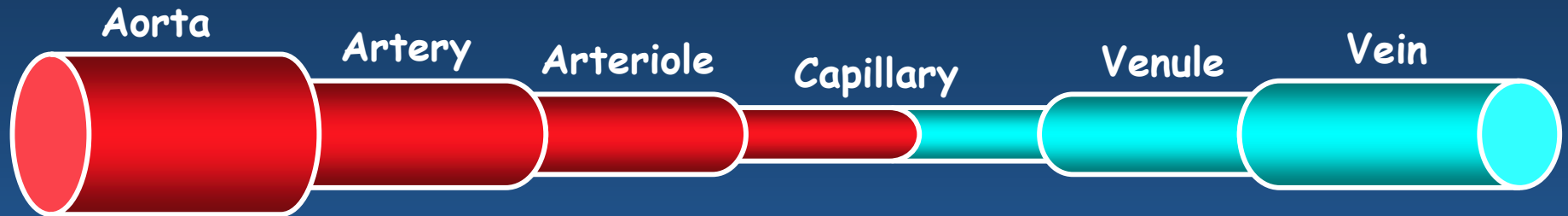
- **Hereditary Hemorrhagic Telangiectasia (HHT) or Osler-Webber-Rendu disease**
- **Systematic disease primarily involving skin and mucous membranes, and often the GI tract**
- **Autosomal dominant disease with positive family history in 80% of cases**
- **After epistaxis which occurs in 80% of individuals, GI bleed is the most frequent presentation and occurs in 10-40% of cases**

# Arteriovenous Malformations (AVM's)

- Irregular meshwork of structurally abnormal medium to large ectatic vessels
- Unlike small vessel ectasias, AVM's can be distributed in all layers of the bowel wall
- AVM's may present anywhere at any age, although some are thought to be congenital



# Vasculitis



Goodpasture

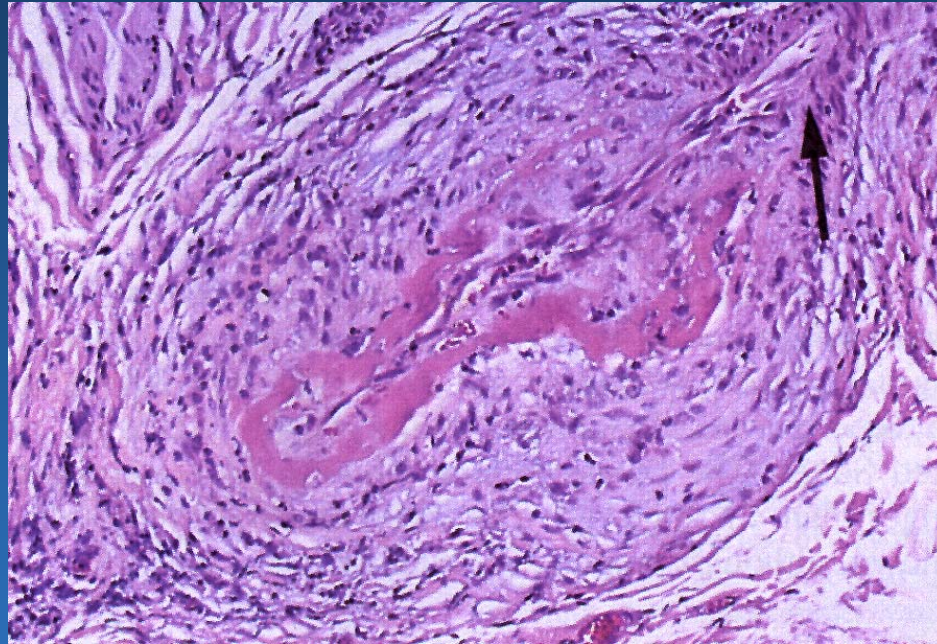
Giant-Cell Arteritis,  
Takayasu Arteritis

Microscopic Polyangiitis, Wegener's,  
Churg-Strauss Syndrome, SLE

Polyarteritis Nodosa,  
Kawasaki Disease

Henoch-Schonlein Purpura

# Vasculitis (PAN)





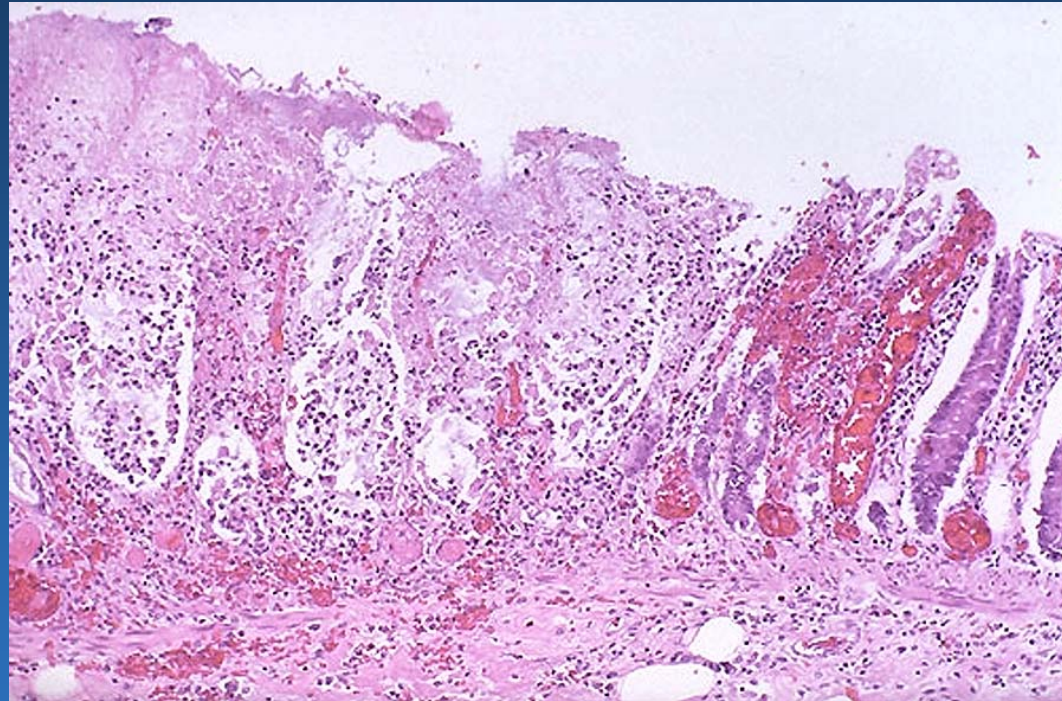
# Vascular Insufficiency

- **Vaso-occlusive Diseases**
  - **Mesenteric arterial occlusion (embolism/thrombosis)**
  - **Mesenteric vein thrombosis**
  - **Bowel strangulation (volvulus, hernia)**
- **Non-Occlusive Vascular Insufficiency**
  - **Systemic hemodynamic disturbances**
  - **Local hemodynamic disturbances**

# Ischemic colitis



# Ischemic Colitis

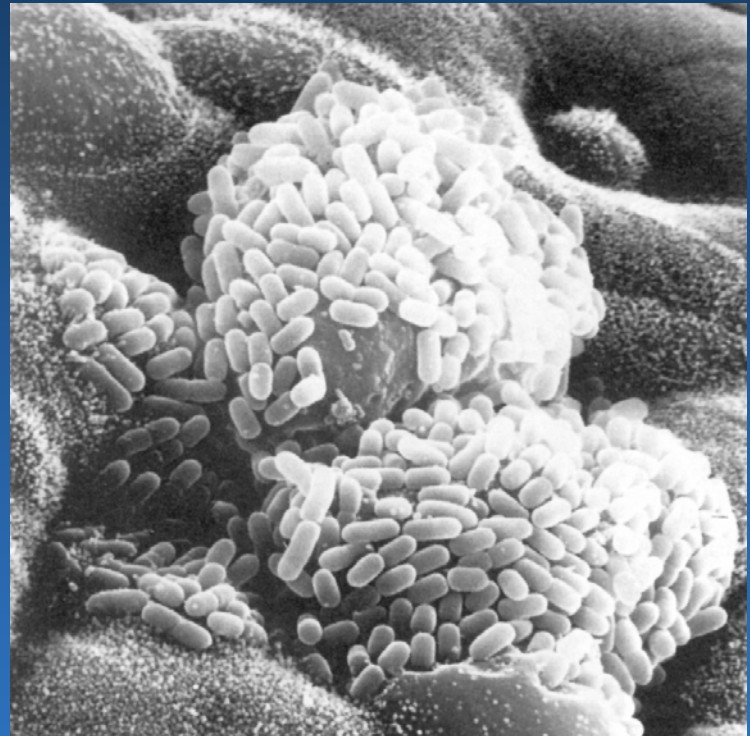


# Infectious Enteritis

- The most common GI problem worldwide
- Most symptomatic infections produce diarrhea and some produce malabsorption
- Diagnosis is most often by stool culture or O&P
- Organisms **rarely** produce a pathognomonic pattern of injury

# Mechanism of Injury: Toxin Production

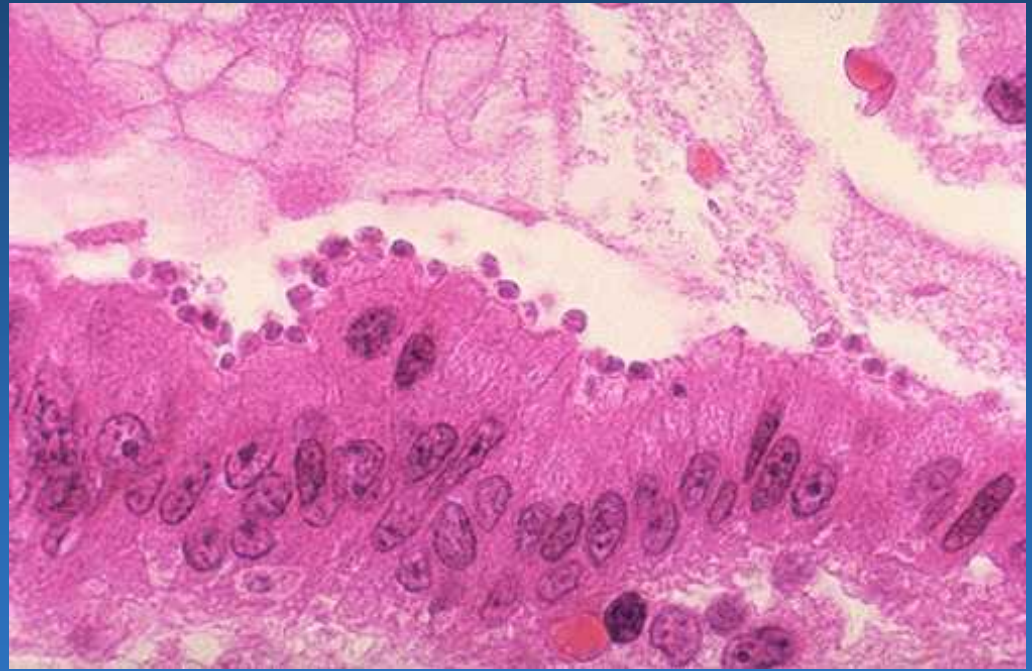
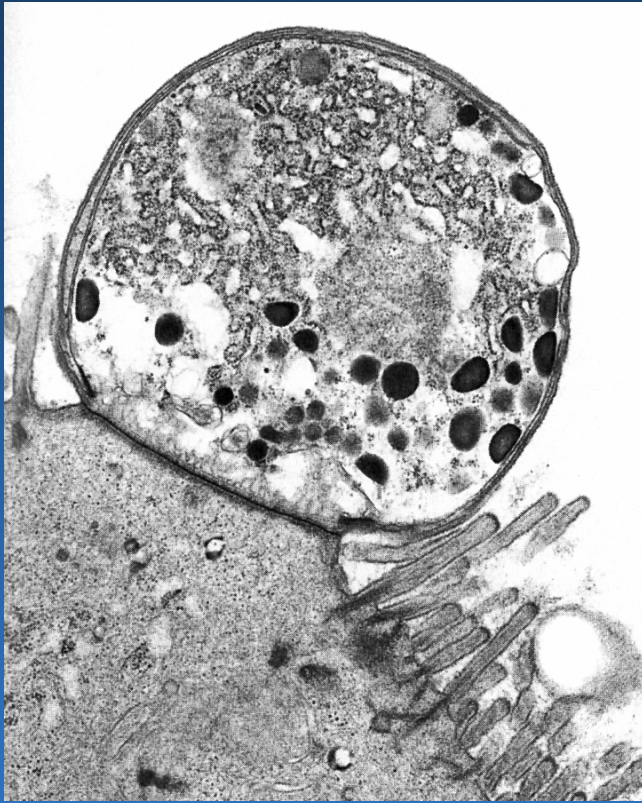- **V. cholera**
- **E. coli**
- **“Food poisoning”**
  - **Staphylococcus**
  - **Clostridium**



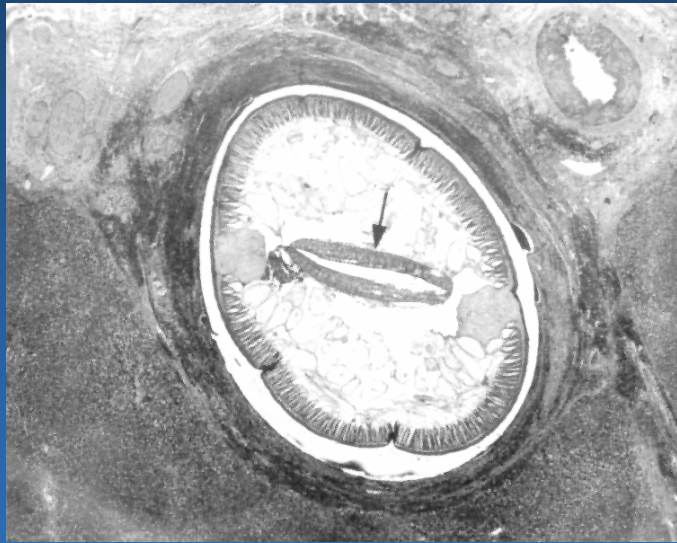
# Mechanism of Injury: Invasion

- **Bacteria**
  - Salmonella, shigella, campylobacter, E. coli, yersinia, mycobacteria
- **Protozoa**
  - Cryptosporidia, isospora, microsporidia
- **Viruses**
  - Rotaviruses, adenovirus, CMV, HSV
- **Fungi**
  - Histoplasma, candida

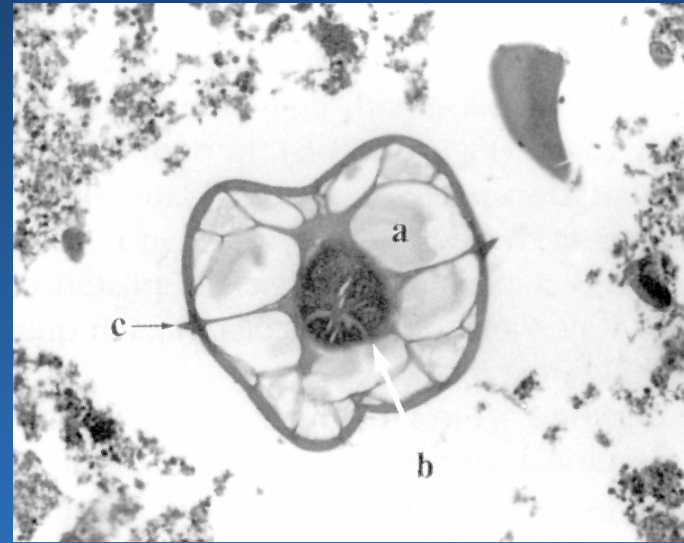
# Cryptosporidiosis



# The Lumen Dwellers



*Ascaris lumbricoides*



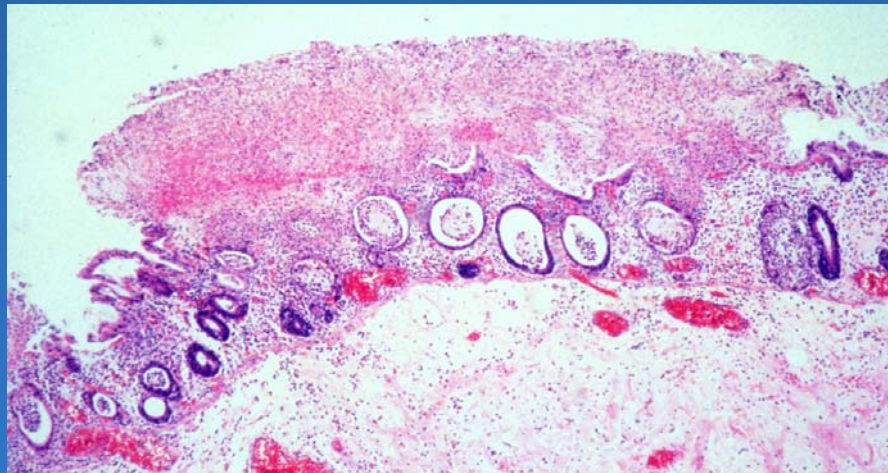
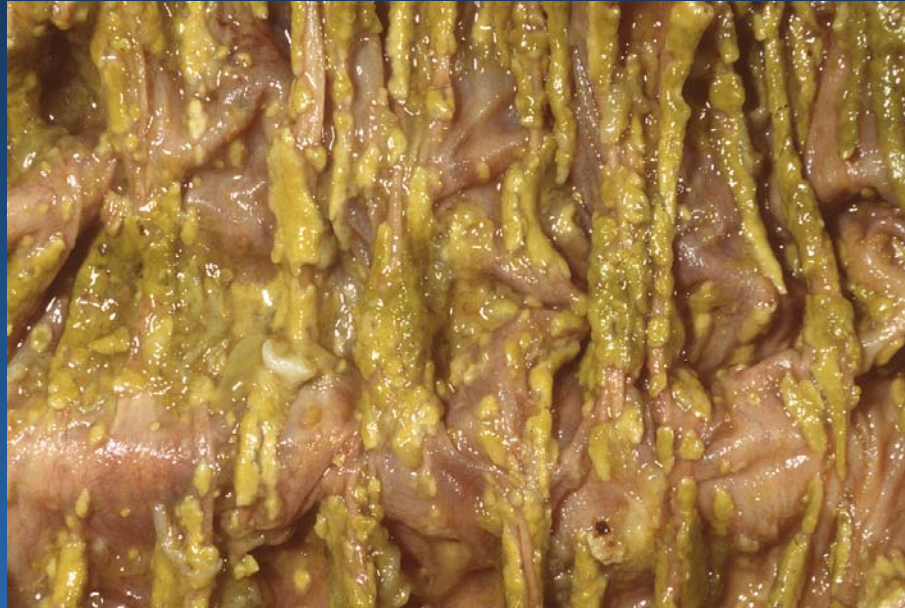*Enterobius vermicularis*



# Antibiotic-Associated Colitis

- **Antibiotic-associated pseudomembranous colitis (PMC) is an acute colitis characterized by the formation of an inflammatory exudate**
- **PMC is a toxin-mediated colitis usually caused by *C. difficile* or less commonly by *E. Coli***

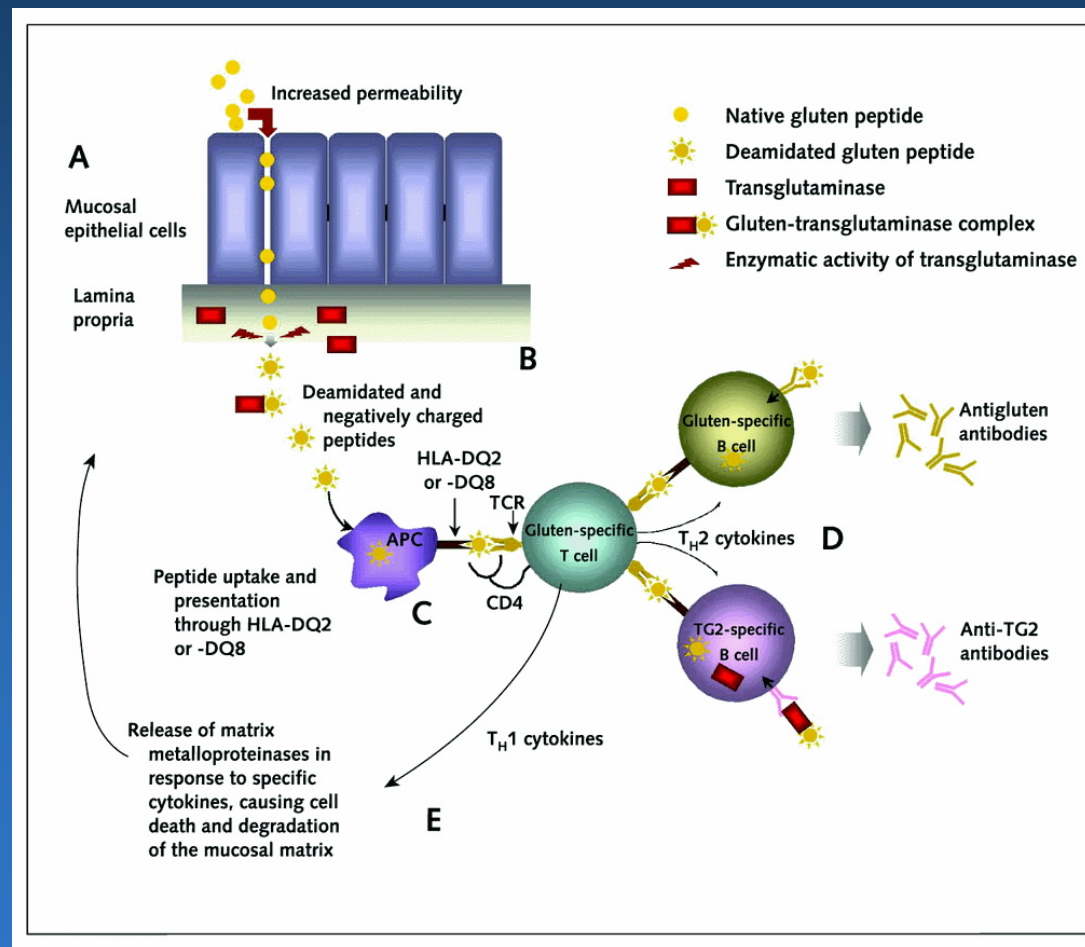
# PMC



# “Immune” Enteropathy: Celiac sprue

- **Gluten-sensitive enteropathy, Celiac disease, Non-tropical sprue**
- **Chronic inflammatory disease of the proximal small intestine with generalized malabsorption**
- **Most common in the Irish, British, and other northern European populations**
- **Immune mediated injury to enterocytes accompanied by **serum antibodies to gliadin**, a component of gluten**

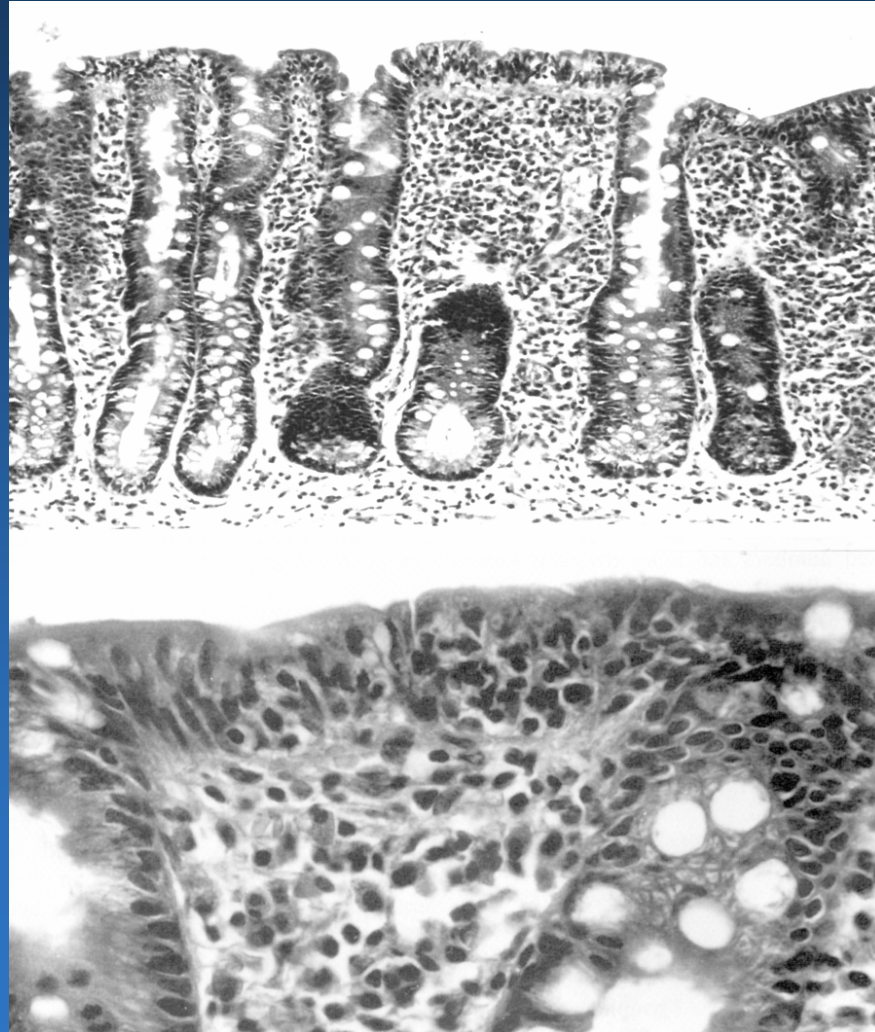
# Celiac disease- Immunologic mechanism of damage



# Celiac Sprue

- **Symptoms:**
  - **Steatorrhea, abdominal distention, flatulence, fatigue, and weight loss**
- **Complications:**
  - **Iron and vitamin deficiency**
  - **Risk of lymphoma (T-cell type)**
- **Extraintestinal manifestation:**
  - **Dermatitis herpetiformis (a pruritic papulovesicular rash with IgA deposits at the dermoepidermal junction)**

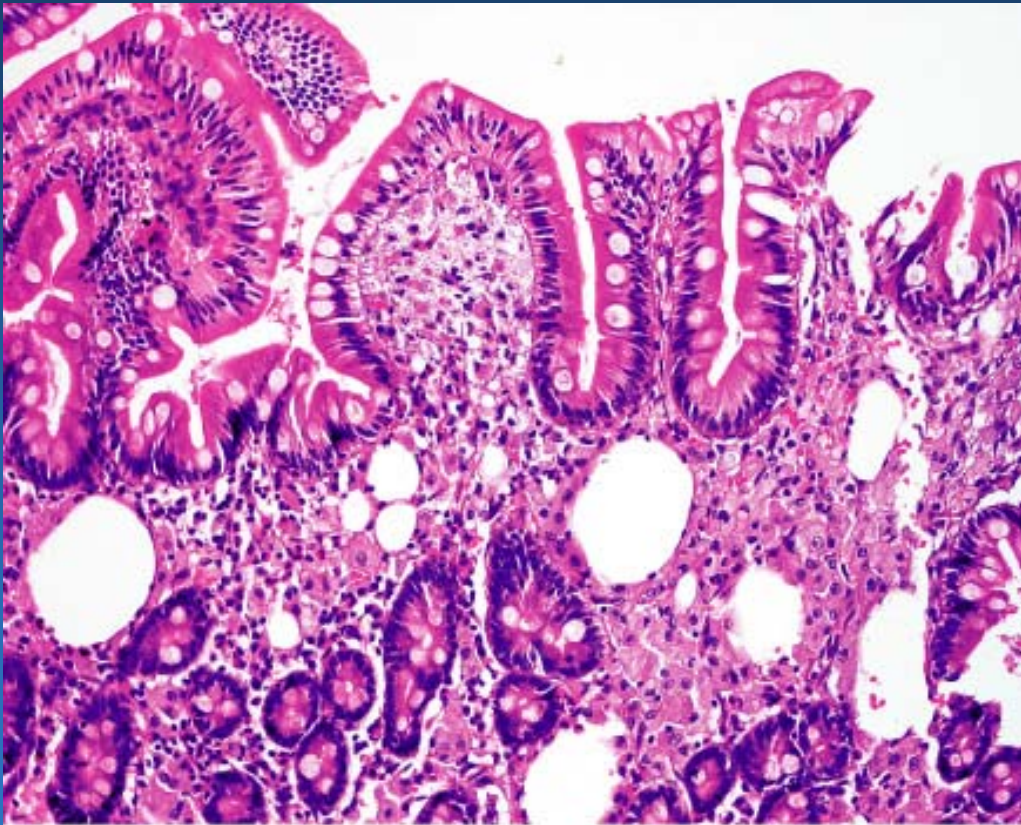
CD



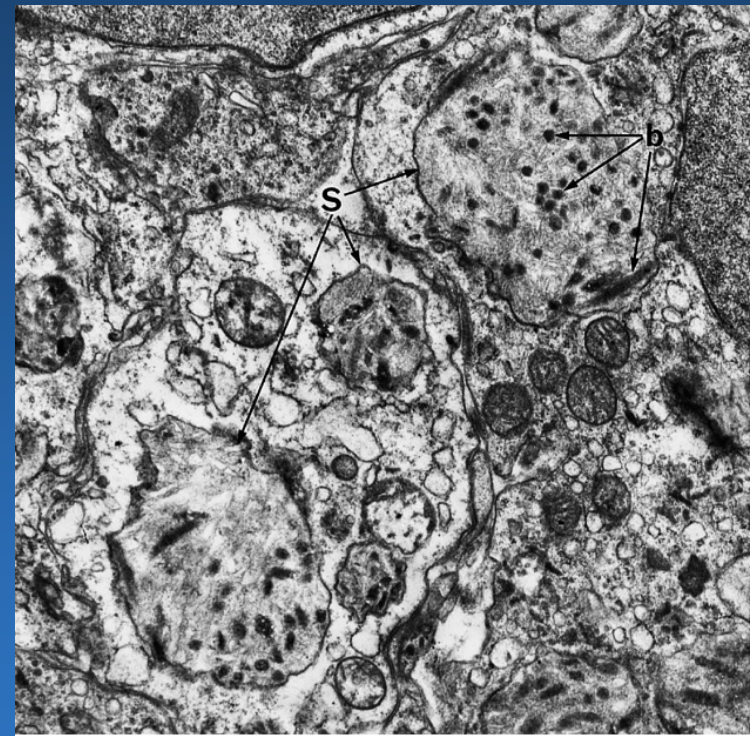
# Malabsorption- other causes

- **Immune conditions**
- **Hypersensitivity/allergy/eosinophilic gastroenteritis**
- **Infection- Whipple's dis., tropical sprue, bacterial overgrowth**
- **Nutritional deficiencies-**
- **Inherited- Microvillous inclusion dis.,lymphangiectasia**
- **Infiltrative disorders- amyloidosis, lymphoma**
- **Systemic disorders- lipid storage**
- **Other- short bowel**

# Whipple's disease



© Elsevier Inc 2004 Rosai and Ackerman's Surgical Pathology 9e

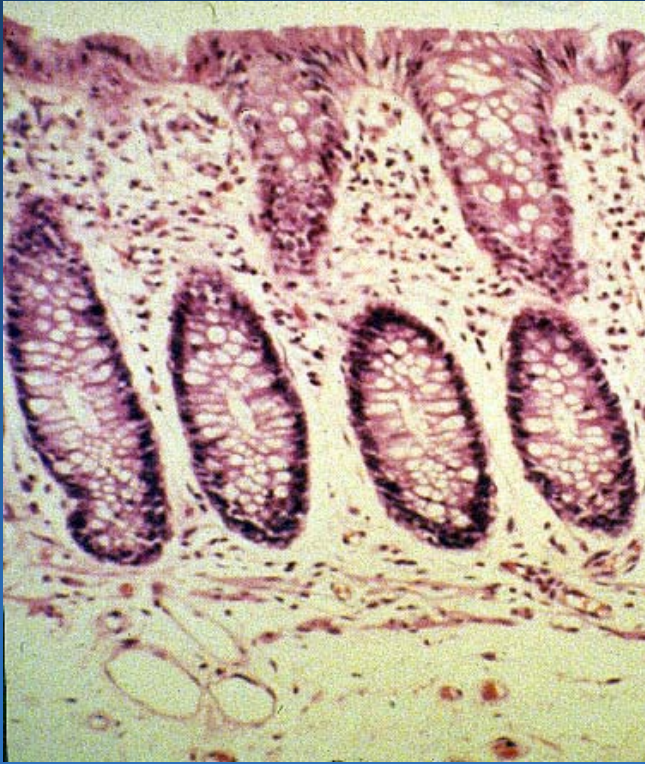

© Elsevier Inc 2004 Rosai and Ackerman's Surgical Pathology 9e

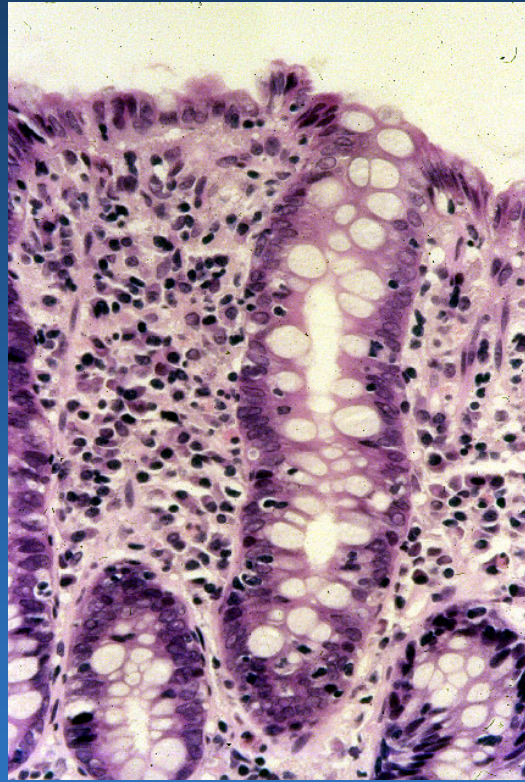


# **Collagenous, lymphocytic colitis**

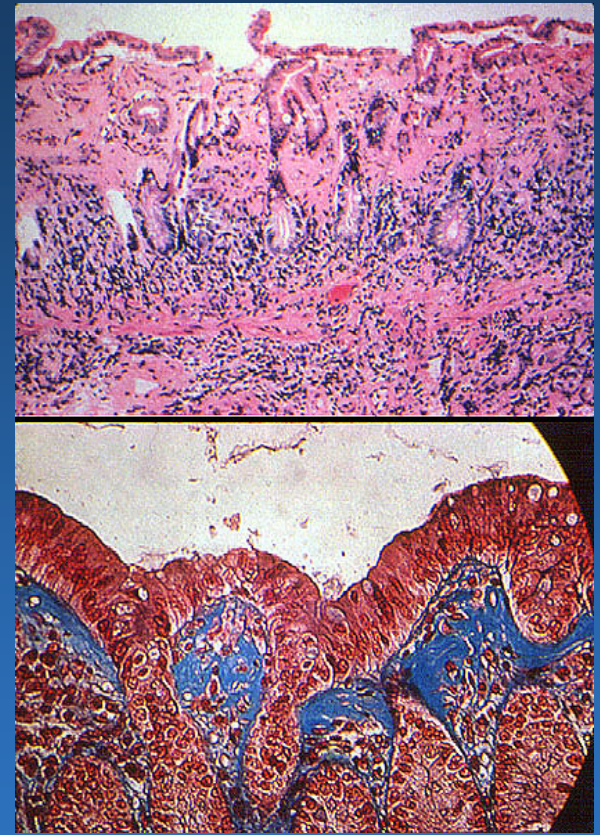
- **Collectively, “microscopic colitis”**
- **Middle aged to elderly adults**
- **Chronic watery diarrhea**
- **Endoscopically normal mucosa**



Normal



Lymphocytic

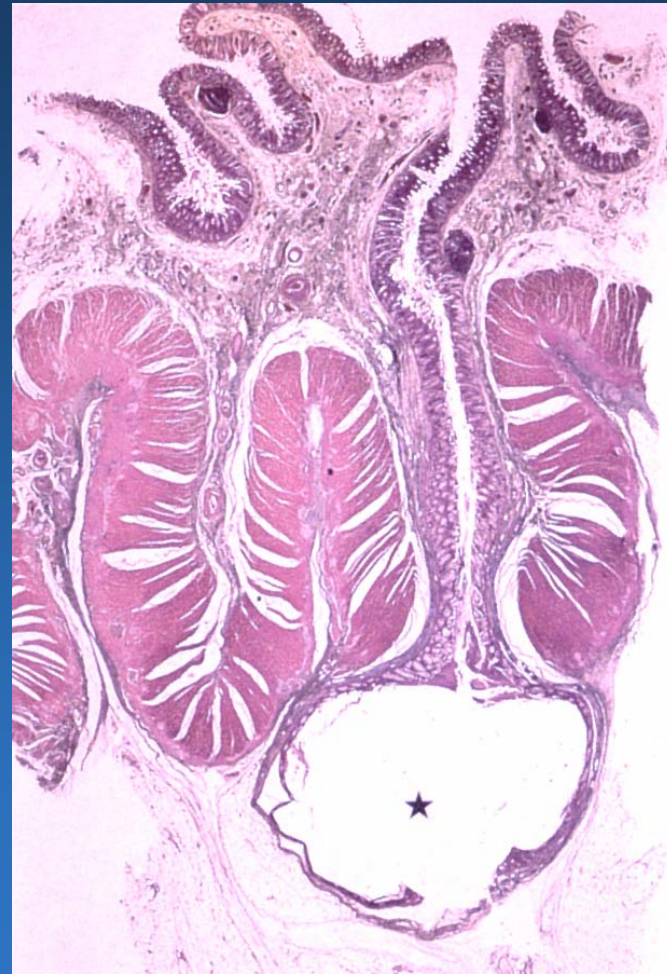
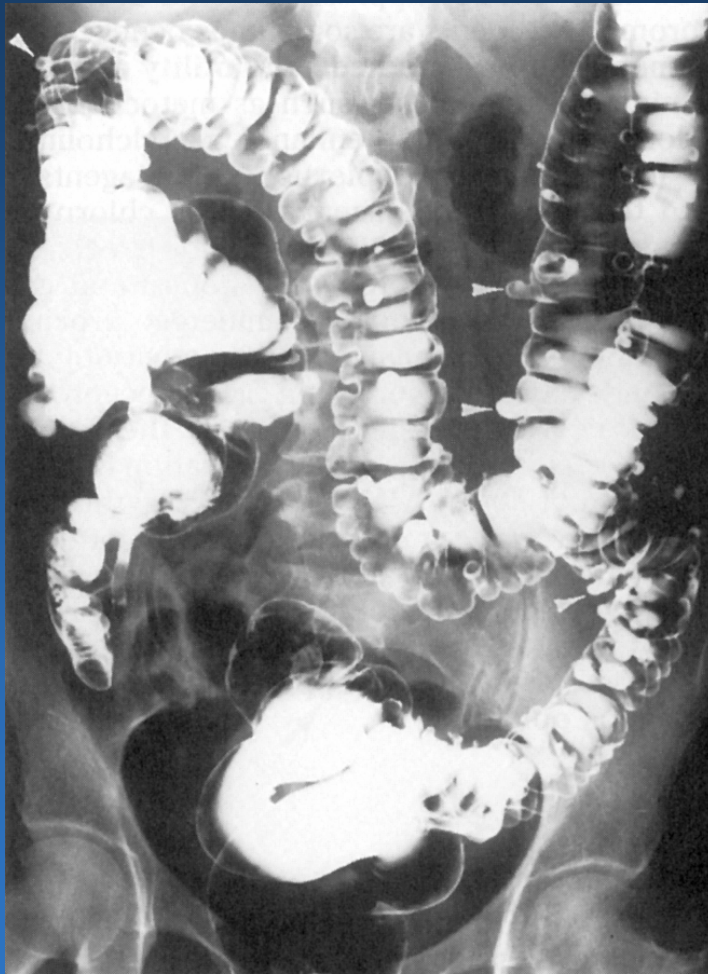


Collagenous

# Diverticulosis Coli

- **Acquired colonic diverticula are present in nearly half of the population over the age of 50**
- **Diverticula are associated with low-fiber, low-residue diets**
- **Etiology is most likely high intraluminal pressure required for propulsion of hard, small stools**
- **Complications include hemorrhage, acute diverticulitis, perforation, fistula formation**

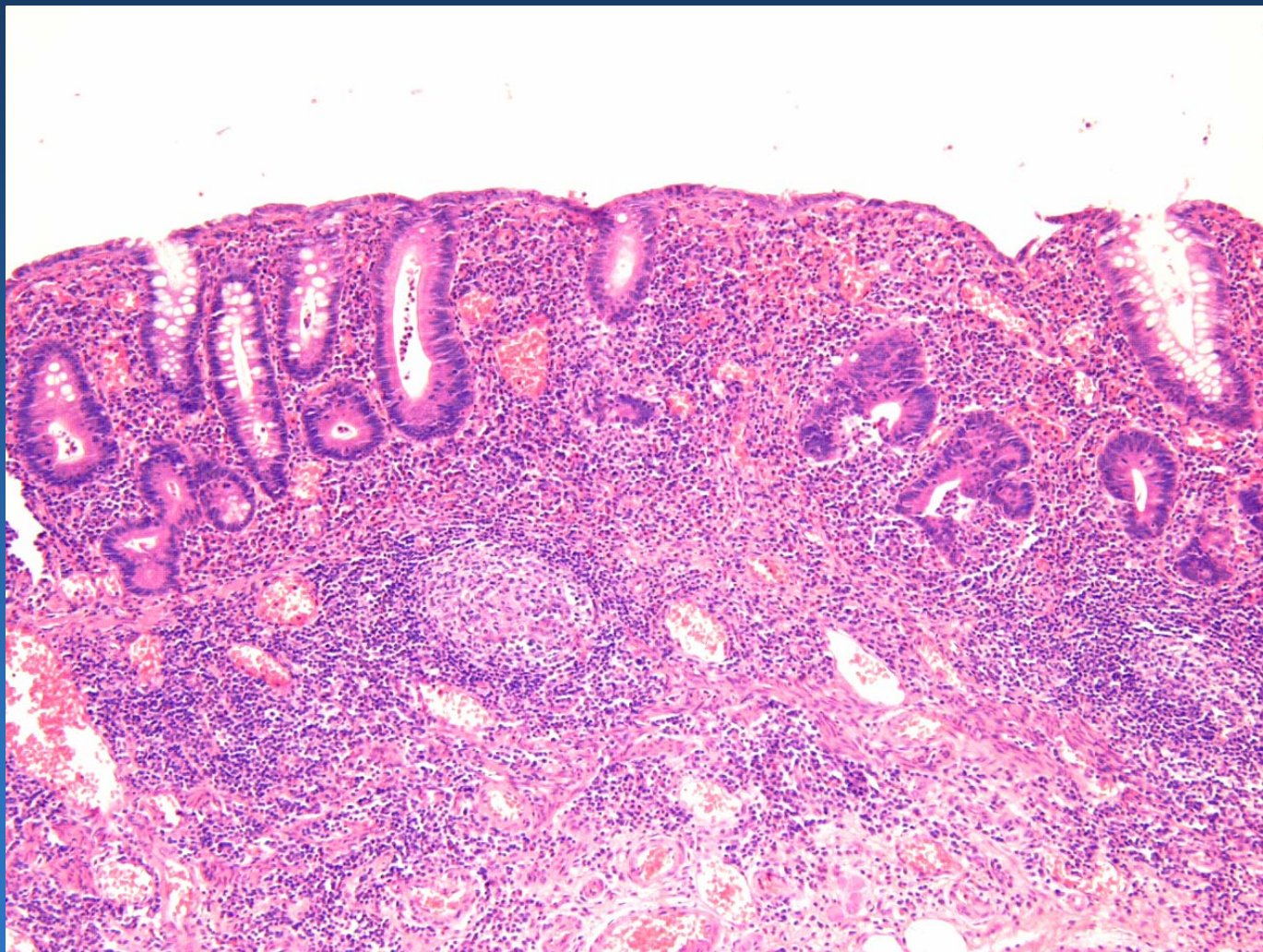
# Diverticulosis Coli



# Idiopathic Inflammatory Bowel Disease (IBD)

- Chronic, relapsing, **idiopathic** inflammatory disease of the GI tract
- Crohn's Disease
  - Transmural granulomatous disease affecting any portion of the GI tract
- Ulcerative Colitis
  - Superficial, non-granulomatous inflammatory disease restricted to the colon

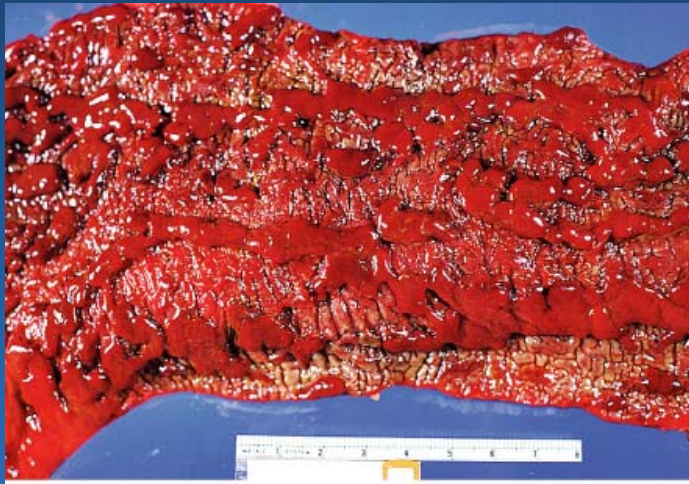# Chronic Colitis



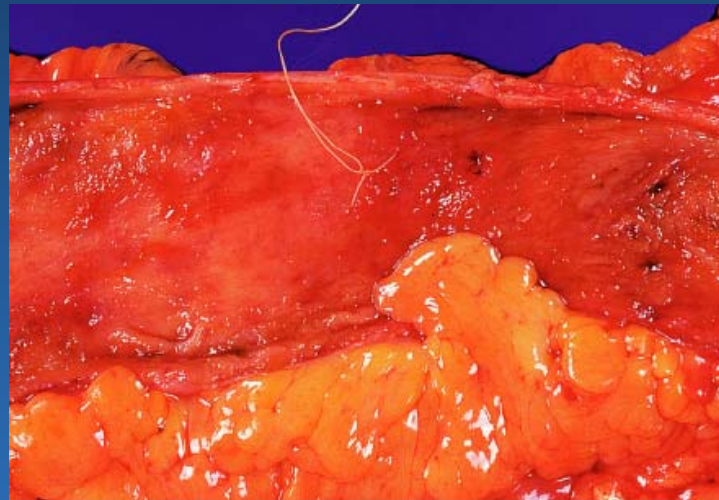
# Ulcerative Colitis

- **Bloody mucoid diarrhea, rarely toxic megacolon**
- **Can begin at any age, peaks at 20-25 years**
- **Annual incidence of ~10 per 100,000 in US**
- **Negligible risk of cancer in the first 10 years, but 1% per year risk of cancer thereafter**
- **Good response to total colectomy if medical therapy fails**

# Ulcerative colitis- gross



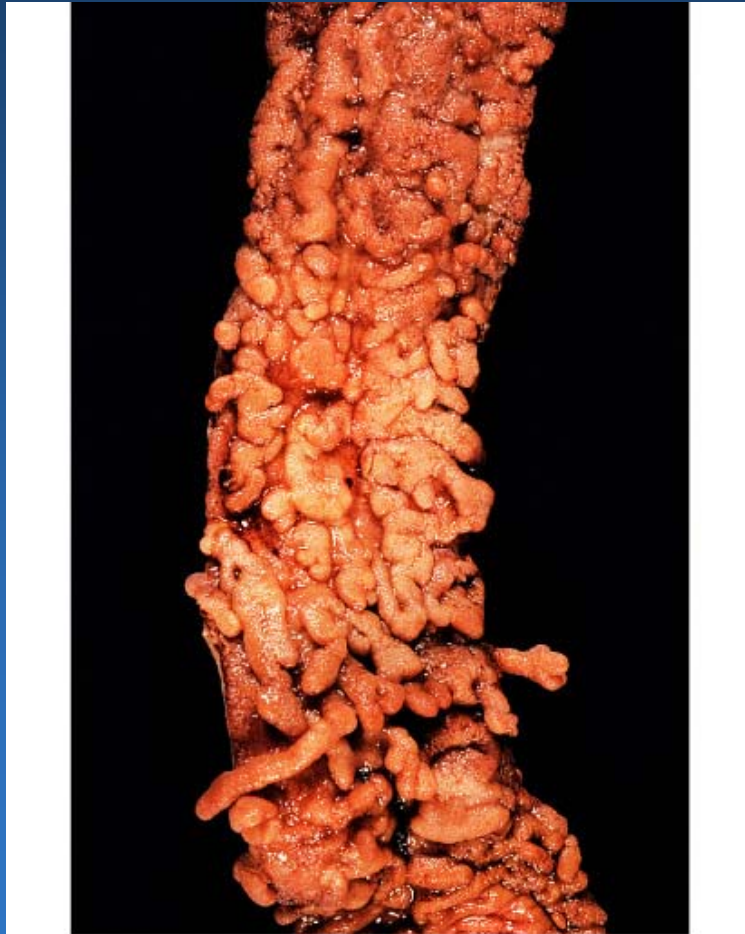© Elsevier Inc 2004 Rosai and Ackerman's Surgical Pathology 9e



© Elsevier Inc 2004 Rosai and Ackerman's Surgical Pathology 9e

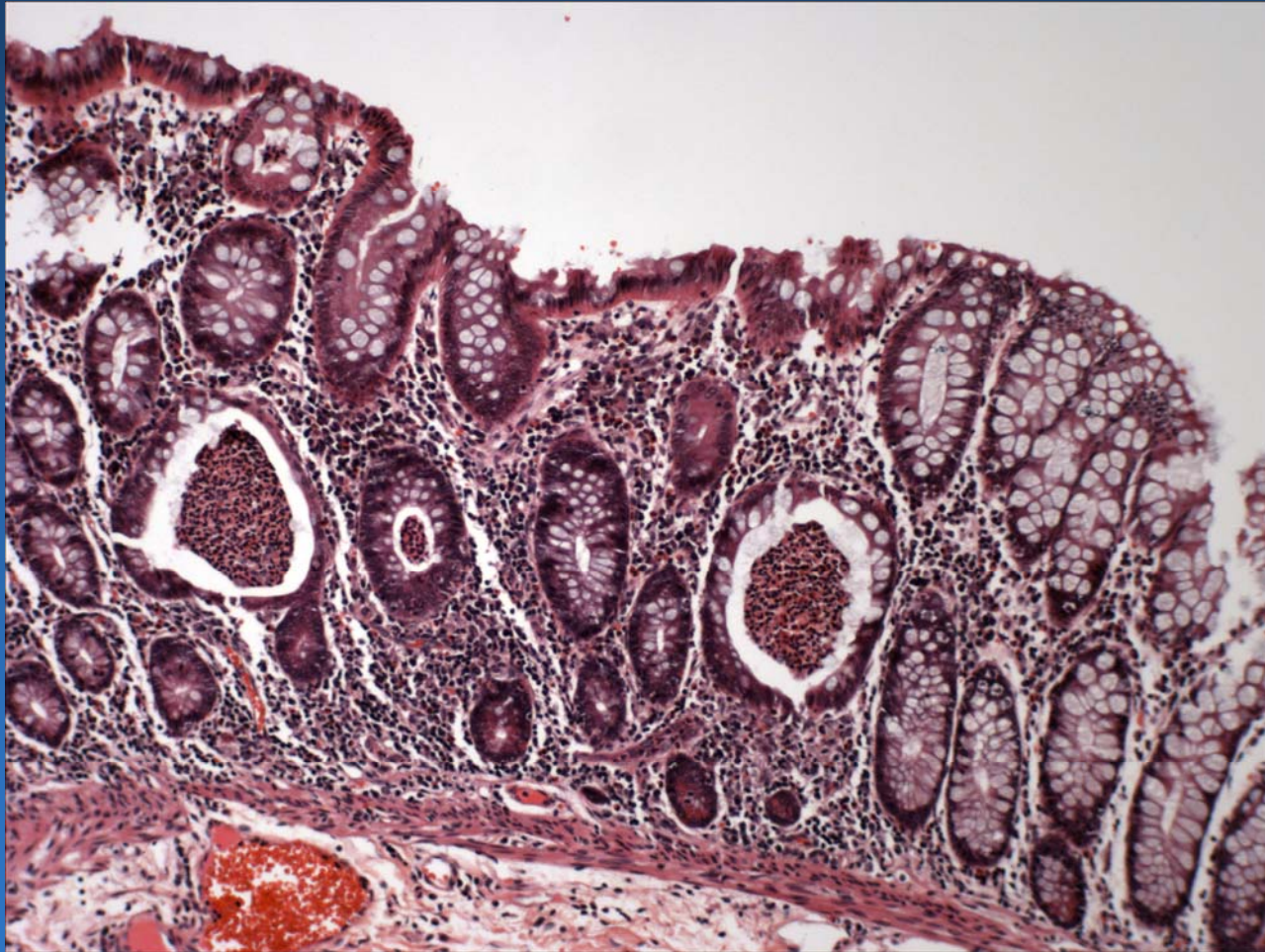


# Ulcerative colitis- pseudopolyps



© Elsevier Inc 2004 Rosai and Ackerman's Surgical Pathology 9e

# UC- microscopic



# Crohn's Disease

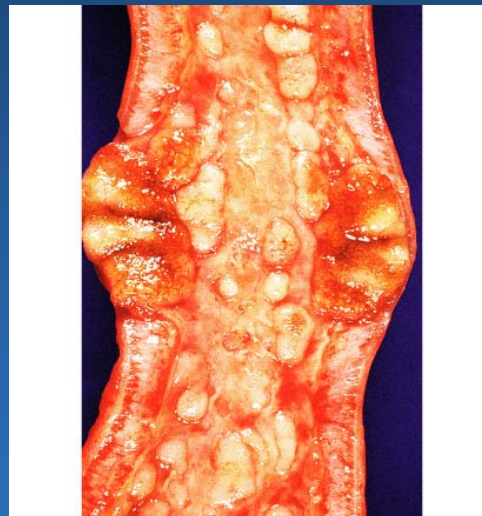
- Variable and elusive clinical presentation with diarrhea, pain, weight loss, anorexia, fever
- Can begin at any age, peaks at 15-25 years
- Annual incidence of ~3 per 100,000 in US
- Many GI complications and extracolonic manifestations
- Risk of cancer less than in UC
- Poor response to surgery

# Crohn's disease- gross appearance



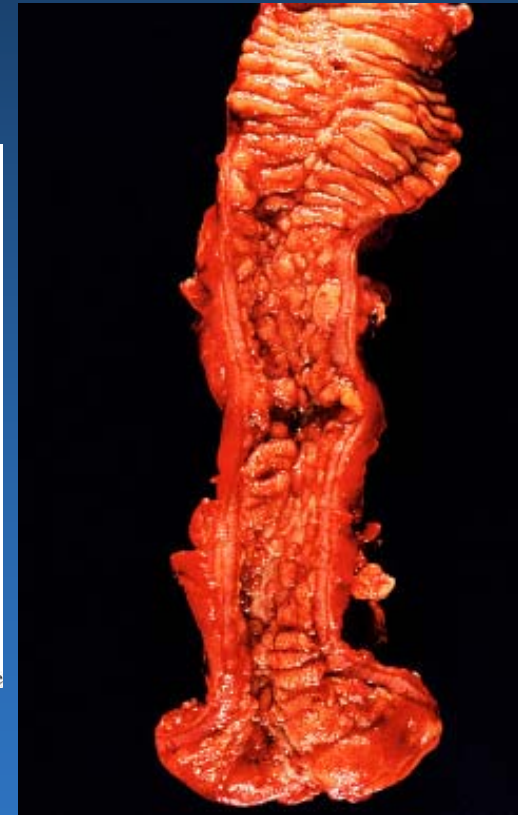
© Elsevier Inc 2004 Rosai and Ackerman's Surgical Pathology 9e

Aphthous ulcer



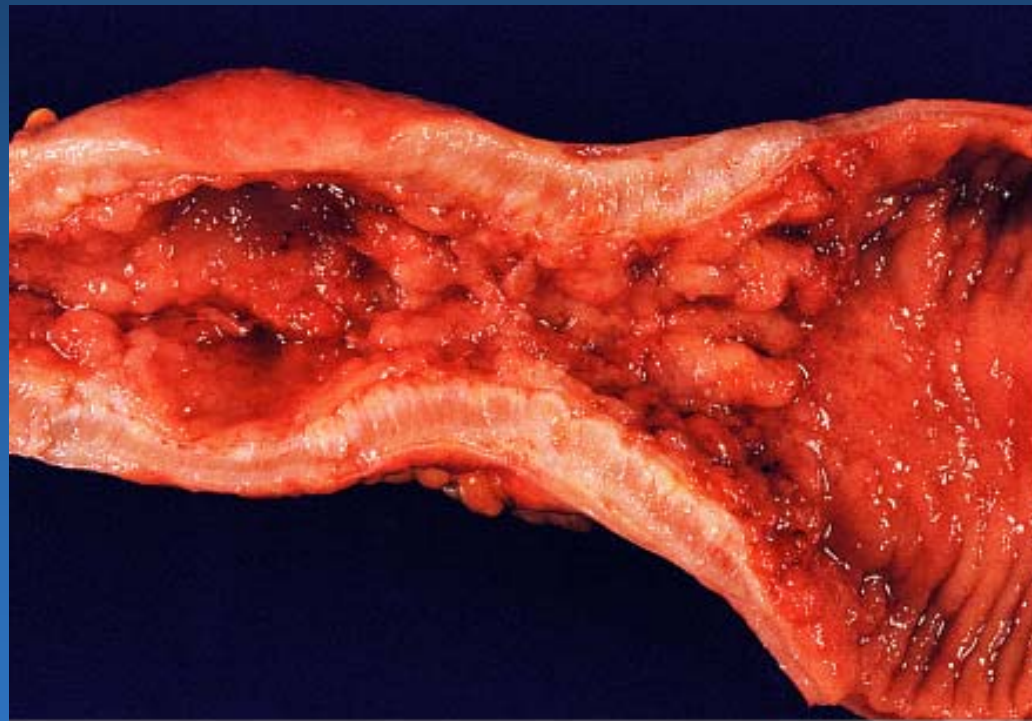© Elsevier Inc 2004 Rosai and Ackerman's Surgical Pathology 9e

“Cobblestoning”

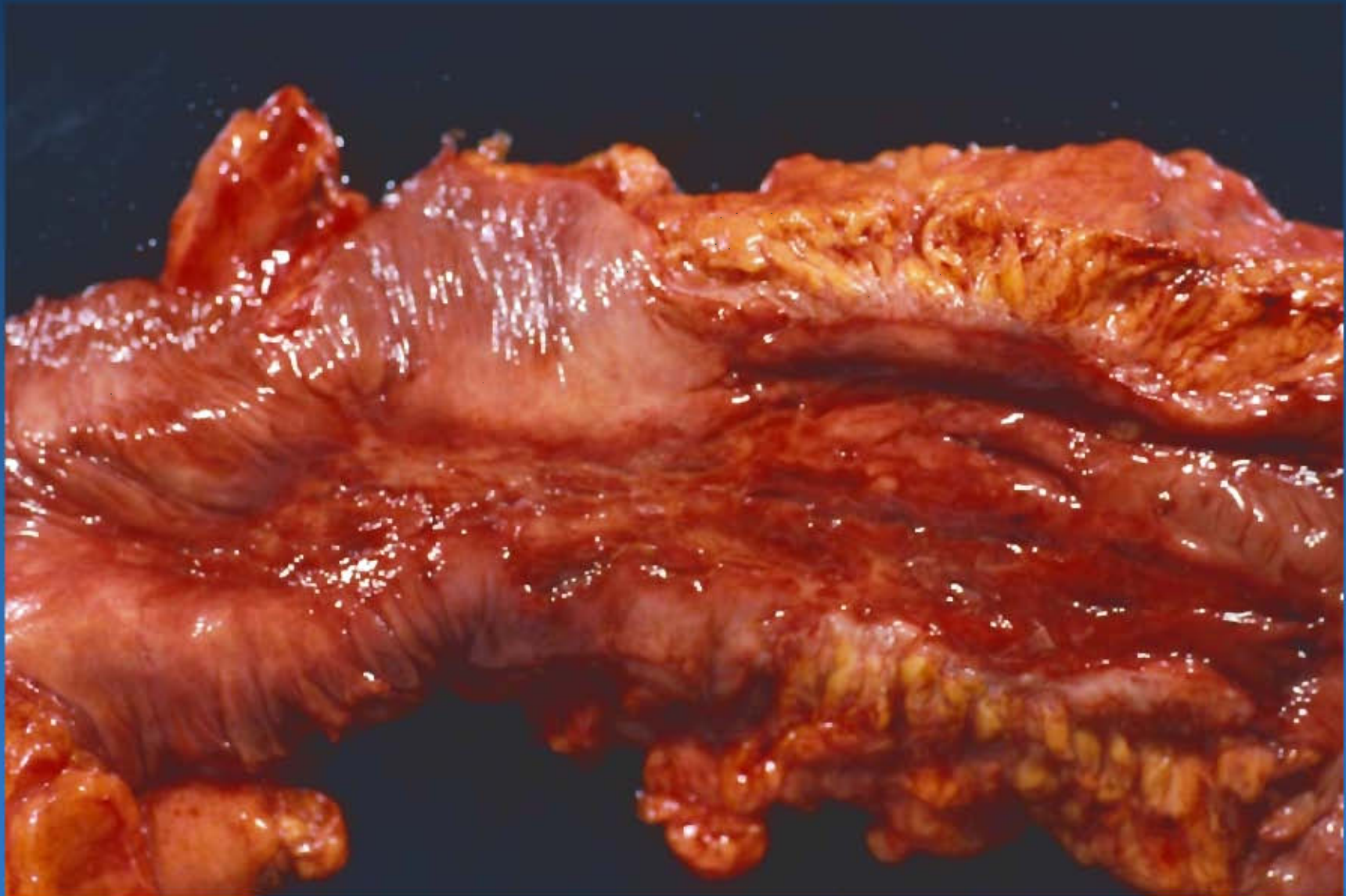


Wall thickening

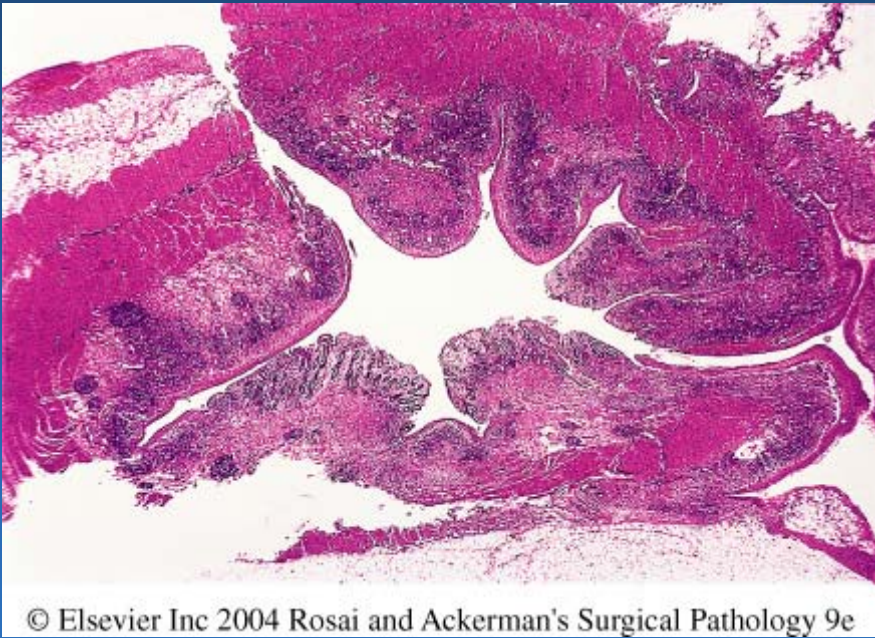
# Crohn's disease- stricture



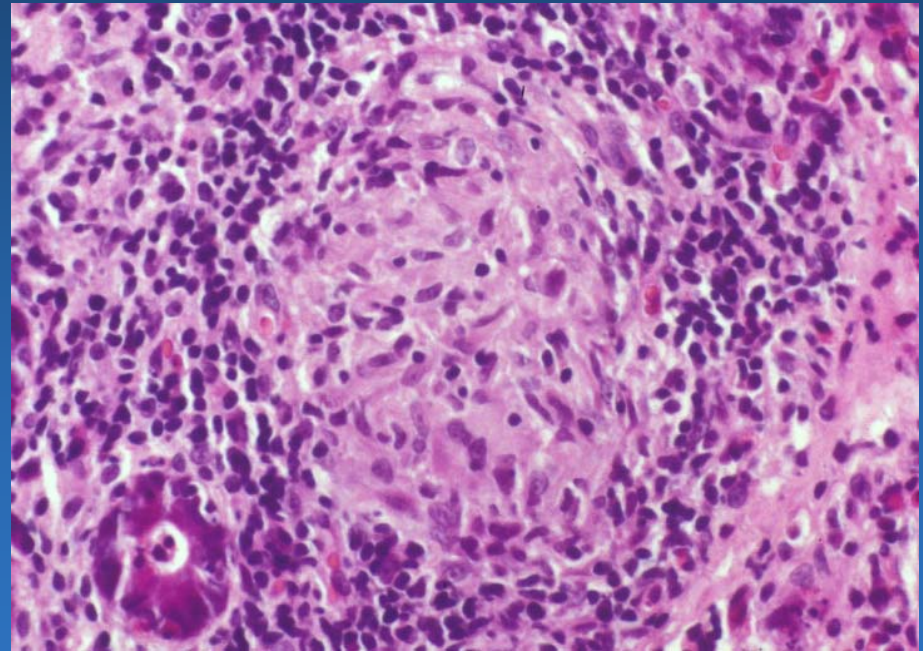
© Elsevier Inc 2004 Rosai and Ackerman's Surgical Pathology 9e



# Crohn's disease- microscopic



Transmural inflammation



Granuloma formation

# Macroscopic Features of CD vs UC

<b>Feature</b>	<b>Crohn's</b>	<b>UC</b>
<b>Region</b>	<b>SI, colon</b>	<b>Colon</b>
<b>Skip areas</b>	<b>Yes</b>	<b>No</b>
<b>Strictures</b>	<b>Yes</b>	<b>No</b>
<b>Wall</b>	<b>Thick</b>	<b>Thin</b>
<b>Creeping fat</b>	<b>Yes</b>	<b>No</b>
<b>Dilatation</b>	<b>No</b>	<b>Yes</b>



# Microscopic Features of CD vs UC

<b>Feature</b>	<b>Crohn's</b>	<b>UC</b>
<b>Granulomas</b>	<b>Yes</b>	<b>No</b>
<b>Ulcers</b>	<b>Fissuring</b>	<b>Superficial</b>
<b>Inflammation</b>	<b>Transmural</b>	<b>Mucosal</b>
<b>Sinuses</b>	<b>Yes</b>	<b>No</b>
<b>Fistulas</b>	<b>Yes</b>	<b>No</b>
<b>Fibrosis</b>	<b>Marked</b>	<b>Minimal</b>